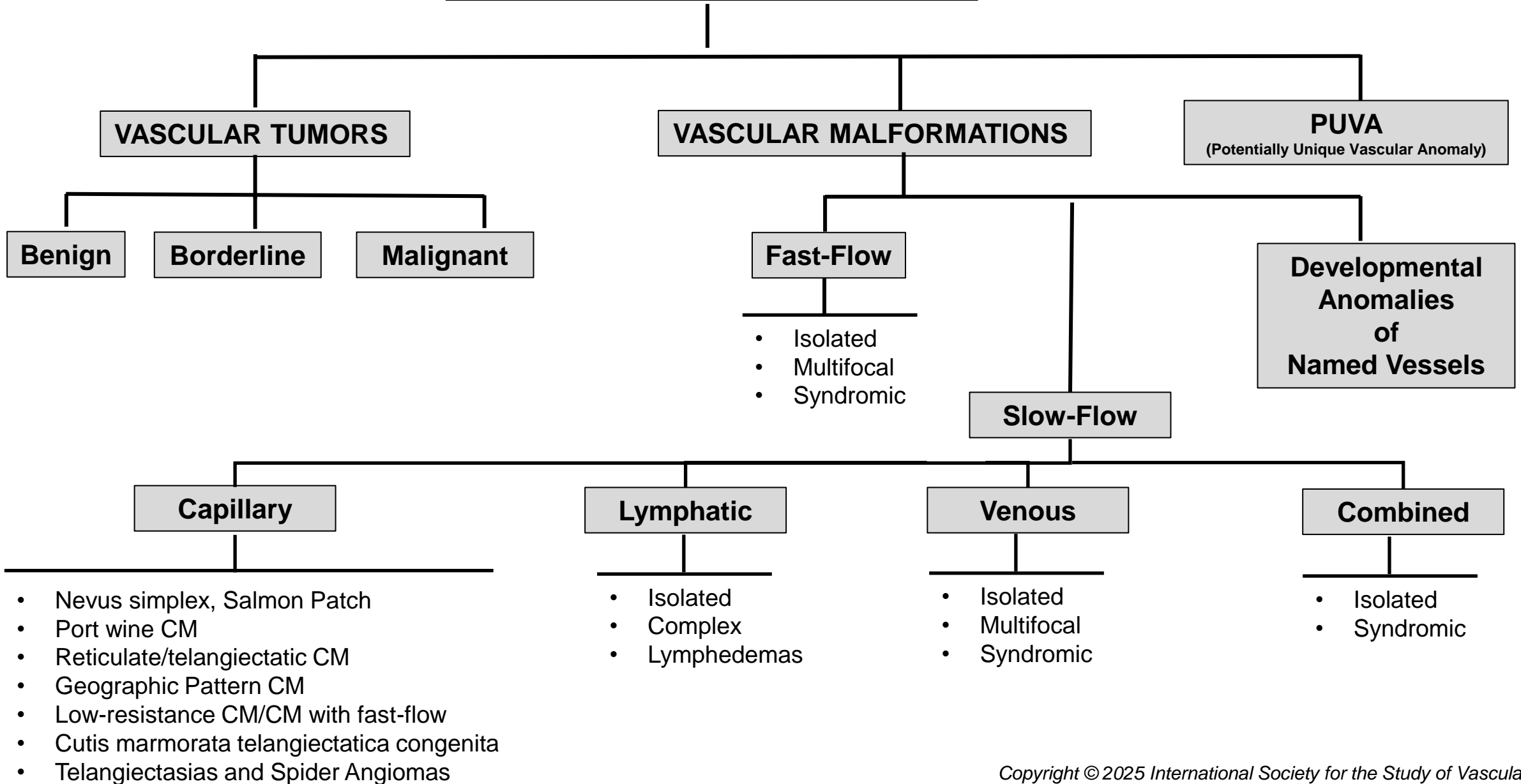


VASCULAR ANOMALIES



VASCULAR TUMORS

Benign*

- Infantile hemangioma
- Congenital hemangioma
- Tufted angioma
- Cherry angioma
- Epithelioid hemangioma
- Cutaneous epithelioid angiomatous nodule
- Pyogenic granuloma (lobular capillary hemangioma)
- Spindle-cell hemangioma
- Hobnail hemangioma
- Microvenular hemangioma
- Anastomosing hemangioma
- Glomeruloid hemangioma
- Papillary hemangioma
- Acquired elastotic hemangioma
- Intravascular papillary endothelial hyperplasia (Masson tumor)
- Littoral cell hemangioma of the spleen
- Placental chorioangioma
- Eccrine angiomatous hamartoma
- Reactive angioendotheliomatosis
- Bacillary angiomatosis

Borderline

- Kaposiform hemangioendothelioma
- Retiform hemangioendothelioma
- Papillary intralymphatic angioendothelioma (PILA), Dabska tumor
- Pseudomyogenic hemangioendothelioma
- Polymorphous hemangioendothelioma
- Kaposi's sarcoma
- Composite hemangioendothelioma
- Multifocal lymphangioendotheliomatosis with thrombocytopenia (MLT)

Malignant

- Angiosarcoma
- Epithelioid hemangioendothelioma

*Reactive proliferative vascular lesions are listed with benign vascular tumors

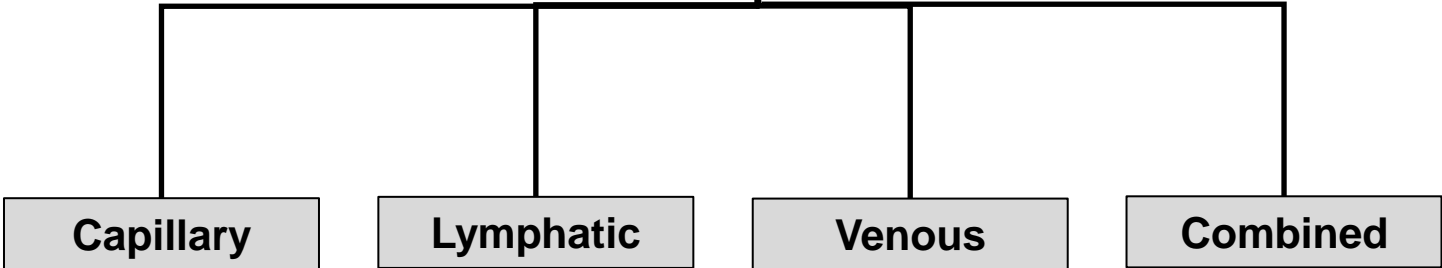
VASCULAR MALFORMATIONS

Fast-Flow

- Isolated
 - AVM
 - Intramuscular Fast-flow Vascular Anomaly
 - AVF
- Multifocal
 - CM-AVM 1 and 2
 - HHT1 and 2 and JPHT
 - PHTS
- Syndromic
 - PHOST (PHTS)
 - Parkes-Weber Syndrome
 - SAMS
 - CAMS

Slow-Flow

Developmental Anomalies of Named Vessels



VASCULAR MALFORMATIONS

SLOW-FLOW

Capillary

- Nevus simplex, Salmon Patch
- Port wine CM (Port wine Birthmark, Nevus flammeus)
 - Isolated (includes Phacomatosis Pigmentovascularis)
 - Syndromic
 - With hypertrophy or extracutaneous disease
 - Sturge-Weber Syndrome
 - DCMO
- Reticulate/telangiectatic CM
 - Isolated
 - Syndromic
 - M-CM
 - MIC-CAP
 - DCMO
- Geographic Pattern CM
 - Isolated
 - Syndromic
 - KTS
 - Associated with CLOVES/Disorders of PROS
- Low-resistance CM/CM with faster flow
 - Isolated
 - Syndromic
 - CM-AVM 1 and 2
 - Parkes-Weber Syndrome
- Cutis marmorata Telangiectatic Congenita
- Telangiectasias and Spider Angiomas
 - Isolated
 - Syndromic
 - CM-AVM 1 and 2
 - HHT 1 and 2 and JPHT (see AVM category)

Lymphatic

- Isolated
 - LM
 - Macrocystic
 - Microcystic
 - Mixed Macro-microcystic
 - Angiokeratoma
- Complex
 - GLA
 - KLA
 - GSD
 - CCLA
 - Isolated
 - Syndromic (RASopathy)
- GLD
- Lymphedemas
 - Primary
 - Isolated
 - Syndromic
 - Secondary

Venous

- Isolated
 - VM
 - Phlebectatic
 - Spongiform
 - VVM
 - FAVA
- Multifocal
 - VMCM
 - MSVM
 - BRBNS
 - GVM
 - HCCVM/CCM
 - VMOS
- Syndromic
 - PHTS
 - CLOVES
 - Mafucci Syndrome
 - Sinus Pericranii

Combined

- Isolated
 - CLVM
 - LVM
 - CLM
 - CVM
 - HCCVM/VVM
- Syndromic
 - PROS
 - KTS (CLVM with hypertrophy)
 - CLOVES
 - CLAPO
 - Proteus Syndrome

Developmental Anomalies of Named Vessels

- Vena cava
- Aorta
- Vein of Galen
- Others